

The official journal of

INTERNATIONAL FEDERATION OF PIGMENT CELL SOCIETIES · SOCIETY FOR MELANOMA RESEARCH

# PIGMENT CELL & MELANOMA Research

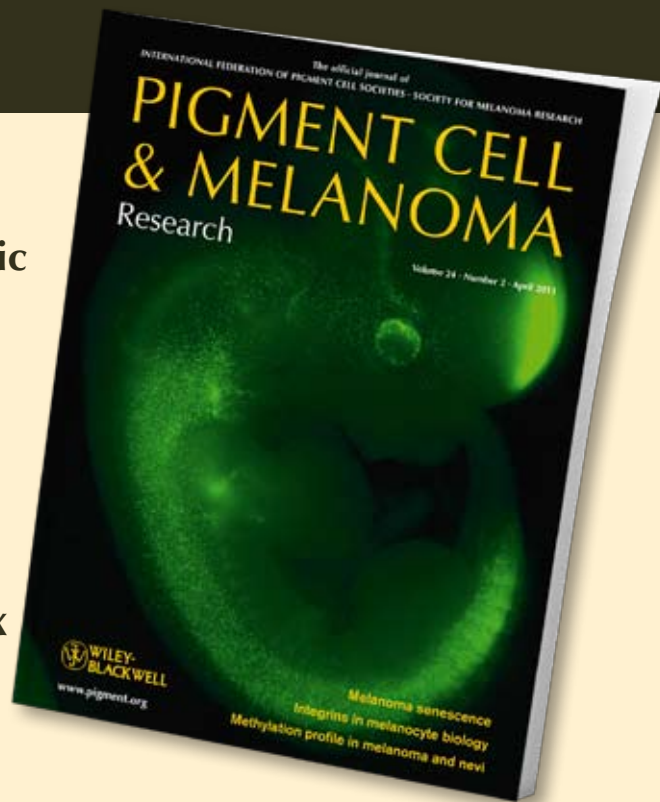
Meeting report from the 2011 international expert meeting on large congenital melanocytic nevi and neurocutaneous melanocytosis, Tübingen

Sven Krengel, Helmut Breuninger, Mark Beckwith and Heather C. Etchevers

DOI: 10.1111/j.1755-148X.2011.00875.x

Volume 24, Issue 4, Pages E1–E6

If you wish to order reprints of this article, please see the guidelines [here](#)



## EMAIL ALERTS

Receive free email alerts and stay up-to-date on what is published in Pigment Cell & Melanoma Research – [click here](#)

Submit your next paper to PCMR online at <http://mc.manuscriptcentral.com/pcmr>

Subscribe to PCMR and stay up-to-date with the only journal committed to publishing basic research in melanoma and pigment cell biology

As a member of the IFPCS or the SMR you automatically get online access to PCMR. Sign up as a member today at [www.ifpcs.org](http://www.ifpcs.org) or at [www.societymelanomaresearch.org](http://www.societymelanomaresearch.org)

To take out a personal subscription, please [click here](#)

More information about Pigment Cell & Melanoma Research at [www.pigment.org](http://www.pigment.org)

# Meeting report from the 2011 international expert meeting on large congenital melanocytic nevi and neurocutaneous melanocytosis, Tübingen

Sven Krenzel, Helmut Breuninger, Mark Beckwith and Heather C. Etchevers

**CORRESPONDENCE** H. C. Etchevers, e-mail: heather.etcchevers@inserm.fr

doi: 10.1111/j.1755-148X.2011.00875.x

## Introduction

Nearly 150 participants from 14 countries participated in the multidisciplinary 2011 expert meeting for large and giant congenital melanocytic nevi (GCMN) and neurocutaneous melanocytosis (NCM). Congenital cutaneous nevi with a projected adult diameter of over 10 or 20 cm are considered 'large' or 'giant', respectively. Neurocutaneous melanocytosis is a neurological disorder characterized by abnormal aggregations of nevomelanocytes within the central nervous system, in conjunction with a GCMN. It can be asymptomatic or present as variably severe and progressive neurological impairment, sometimes resulting in death. Affected patients with GCMN or NCM and their families are faced with psychosocial difficulties, complex therapeutic management decisions, and the risk of neurological problems and malignant degeneration. The goal of this conference was to enrich a traditional academic exchange by actively encouraging the participation not only of the speakers but also of the audience, to inform each about relevant advances in fields they may not otherwise follow and to accomplish tangible group measures. To attain this goal, we held moderated but informal discussions after each talk, extended restorative periods during which speakers and physician trainees mingled with an often unwittingly excluded type of expert – representatives of patient advocacy groups from around the world, and final summary and brainstorming sessions. The conference was conducted in English but there were enough multilingual participants to facilitate comprehension and exchange.

Twenty-one speakers from Germany, Switzerland, France, the United States, Great Britain, and Israel contributed to the scientific program (Table 1). A parallel and coincident program was attended by patient association delegates from these same countries, as well as Portugal, Spain, the Netherlands, Macedonia, and Australia, for most of whom this was the first opportunity to network in person with analogous groups. As an important result of this meeting, the patient associations committed to supporting and encouraging their mem-

bers to participate in a single worldwide GCMN/NCM registry and to spearhead an Internet-based, multilingual, and curated GCMN/NCM patient information portal through which patients and researchers can access the registry.

## Molecular, cell, and developmental biology

In his keynote lecture, *Miguel Reyes-Múgica* (Pittsburgh) reviewed a few of the wide range of diseases that are grouped under the term 'neurocristopathies'. These pathologies include neuroblastoma, the most common malignant solid extracranial tumor of children; Hirschsprung disease, a deficiency in the development of the enteric nervous system; and different forms of cutaneous and neurocutaneous melanocytic disorders. Because of the endogenous migratory aspect of neural crest cell (NCC) behavior during embryonic development, the still images seen by pathologists of melanocytic proliferations must be placed in a dynamic context; for example, the concept of 'Abtropfung' that has enjoyed a certain vogue for over a century, where (G)CMN would mature from the predominant localization of melanocytes in the epidermis down into the deeper layers of the skin, has been fully discredited by both histological observations and recent findings that melanocytic precursors normally reside in the dermis, the meninges, and along peripheral nerves. From these locations, they can not only give rise to pigmented nevi but also to extremely bulky proliferations that may resemble neurofibromas, rhabdomyosarcomas, or malignant melanoma without necessarily presenting all the canonical features. Defining new cytogenetic and histological markers for these GCMN-associated tumors will help determine their prognosis and optimal treatment.

Because invasive and proliferative behavior is a normal characteristic of NCC, understanding the effects of timing and embryonic context is crucial to discovering the molecular bases of isolated and syndromic forms of GCMN. *Heather Etchevers* (Marseille), in her talk about signaling pathways in neural crest and early melanocyte

**Table 1.** Scientific talks held at the 2011 Expert Meeting on large and giant congenital melanocytic nevi (GCMN) and neurocutaneous melanocytosis (NCM)

---

Session 1: Overview and neurological aspects of CMN	
Rudolf Happle:	A fresh look at congenital melanocytic nevi
Ashfaq Marghoob:	Epidemiology, classification, and clinical management of congenital melanocytic nevi
Alon Scope:	Dermoscopy and confocal reflectance microscopy in the surveillance of congenital melanocytic nevi
Yasmin Khakoo:	Spectrum of neurological dysfunction in NCM
Marcos Tatagiba:	Neurosurgical management of NCM
Session 2: Integrating the CMN patient experience	
Mark Beckwith:	Patient groups: International initiatives
Ornella Masnari:	Stigma experiences in children and adolescents with a facial difference
Ashfaq Marghoob/Harper Price:	A cooperative international registry of CMN and NCM
Session 3: Biological bases of CMN	
Miguel Reyes-Múgica:	The neurocristopathies: a pathologist's viewpoint
Heather Etchevers:	Signaling pathways in neural crest and early melanocyte development
Bernhard Wehrle-Haller:	The kit-ligand/c-kit receptor interaction: potential therapies for pigmented lesions
Veronica Kinsler:	The genetics of congenital melanocytic naevi
Session 4: Surgical options for CMN treatment	
Clemens Schiestl/Thomas Biedermann:	Tissue engineering of skin: best wishes from the petri dishes
Rainer Rempel:	Indications and long-term results of dermabrasion
Helmut Breuning:	Early treatment of large congenital melanocytic nevi by serial power stretching of the skin with intracutaneous butterfly sutures under high tension
Bruce Bauer:	The role of tissue expansion in the treatment of large and giant congenital melanocytic nevi
Session 5: Syndromic aspects of inappropriate proliferation	
Sven Krengel:	Childhood melanoma: a distinct entity?
Pierre Heimann:	Cytogenetic alterations and <i>BRAF</i> / <i>NRAS</i> mutations in congenital melanocytic nevi
Jürgen Bauer/Gisela Metzler:	Proliferative nodules – clinical, histologic and molecular diagnosis
Veronica Kinsler:	Endocrinological aspects of CMN syndrome
Alain Täieb:	Future therapies: lessons from vitiligo and melanoma

---

development, addressed the dynamic expression of some of the molecules involved in pigment cell fate specification. The temporal progression of melanocyte differentiation mobilizes signaling cascades well known for their later implication in carcinogenesis. These include tyrosine kinase receptors, such as KIT and MET, and their intracellular effectors of the RAS and RAF families and alternative second messenger pathways; influences from the melanocortin 1 receptor (MC1R); and transcriptional control exerted, in particular, by SOX10 on the master pigment cell transcription factor, MITF. Preliminary data demonstrated the persistence of unpigmented, *Sox10*<sup>+</sup> *kit*<sup>+</sup> precursors in both follicular and dermal locations throughout avian skin development, long after the onset of epidermal pigmentation.

*Bernhard Wehrle-Haller* (Geneva) presented both contextual and novel results about the role of the

membrane-bound isoform of Kit ligand (mb-KitL) in the control of the biological properties of melanocytes. Essential, soluble KitL is secreted during development by the embryonic dermamyotome, past which melanoblasts migrate during their maturation. In addition to maintenance signaling, a dimerized, membrane-bound isoform appears to serve as a mechanical anchor for hematopoietic stem cells in their bone marrow niche. Results presented in this talk demonstrated that melanocyte stem cells and potentially within GCMN as well adhere to their niche through mb-KitL/Kit complexes, and that certain protein domains of this complex can be susceptible to enzymatic cleavage, leading to shedding. Disrupting the interaction of mb-KitL and Kit is, therefore, being examined as a potential therapeutic strategy for pigmentary proliferative disorders.

In his comprehensive lecture on cytogenetic alterations and mutations of the *BRAF* or *NRAS* genes for these mediators of MAP kinase signaling in GCMN, *Pierre Heimann* (Brussels) emphasized that in contrast to malignant melanoma, chromosomal abnormalities are rather rare and single in GCMN. He described his group's findings that many more *NRAS* mutations are observed in GCMN, than in medium small and acquired nevi, where *BRAF* mutations are predominant. Among the few GCMN with involvement of *BRAF*, gain-of-function was shown to arise through chromosomal translocation that removed the auto-inhibitory N-terminal regulatory domain of *BRAF* from its protein kinase domain. Other mutations involving *BRAF* regulatory domains represent an alternative mechanism of RAS-MAPK pathway activation in GCMN that harbor neither a *BRAF* nor an *NRAS* coding mutation. Comparison of the transcriptomes of nevocytes to normal melanocytes demonstrated GCMN upregulation of many genes involved in the DNA damage response, and, in particular, stronger expression of the *CDNK2A* p16<sup>INK4A</sup> transcript, probably leading to the cellular senescence most often observed in GCMN.

In his opening address on the genetics of GCMN, *Rudolf Happle* (Freiburg) presented arguments supporting the hypothesis that GCMN represent a superimposed mosaic manifestation of a polygenic trait. Cases of GCMN are very often associated with multiple smaller melanocytic nevi involving the entire body, some congenital and some acquired during early childhood. These small nevi should no longer be termed 'satellite nevi', but Dr. Happle would rather call them 'disseminated background lesions'. At an early developmental stage, loss of a wild-type allele or a post-zygotic mutation at a predisposing gene locus may give rise to a segmental distribution of descendant cells, on an inherited background of the same or an additional predisposing gene locus. The proposed concept would predict that family members of patients with GCMN should show increased numbers of small melanocytic nevi, but this question has so far not been investigated

systematically, although some epidemiological work hints at this result. In addition, the distinction between small and GCMN, and congenital and acquired, may not be so much at the level of the type of mutation but rather a question of its timing in the melanocyte lineage.

*Veronica Kinsler* (London) discussed phenotypic and genetic characteristics of patients with GCMN. More than a third of affected individuals present with positive family history of any sized CMN, and 10% with a family history of adult-onset melanoma. The comparison of a cohort of 222 patients with two independent control cohorts showed that children with GCMN and their parents exhibit certain phototypic characteristics (red hair and freckling in patients and first-degree relatives) significantly more often than the control groups. Accordingly, children with GCMN of over 60 cm diameter projected adult size, which largest size category covaries with the presence of more than 50 additional disseminated nevi, demonstrated highly increased frequencies of common variant alleles in *MC1R*. These alleles were not confined in a mosaic pattern to nevus skin, implying a predisposing rather than a cumulative somatic event in this cohort. At the phenotypic level, the examination of facial features in children with GCMN by experienced dysmorphologists showed interobserver confirmation of typical facial characteristics. Moreover, Dr. Kinsler presented as yet unpublished results that indicate changed hormone levels in some children with GCMN, correlated with effects on longitudinal growth, body mass index, and premature thelarche (onset of breast bud growth) in certain individuals. Taken together, the results presented show a tendency to other measurable phenotypic traits in the GCMN patient population, all potentially caused by the same underlying genetic variations and leading to the proposal of the term 'CMN syndrome'.

### Clinical management of GCMN and melanoma risk

In a comprehensive kickoff lecture, *Ashfaq Marghoob* (New York) asserted that there is insufficient evidence in the literature to recommend strongly for or against surgery on the basis of risk for developing melanoma. While the main impetus for the prophylactic excision of GCMN stems from the knowledge that the relative risk for developing melanoma in GCMN is high, the absolute risk for developing melanoma in association with GCMN is low (range, 0–10%, thought to be somewhere in the middle). Each patient with GCMN requires a tailored management plan based on the size, thickness, nodularity, and location of the nevus, as well as on its potential psychosocial impact and the age of the person seeking treatment. Aspects of all these recommendations were taken up and discussed by many of the following speakers and audience members throughout the meeting. Dr. Marghoob recommended palpation for the detection of tumors in the deep layers of the skin that

are not detectable through dermoscopy and brought up the provocative observation that as yet, there have been no reports of malignant melanoma in 'satellite' (disseminated) CMN. As far as other intralesional tumors, he reports cases with diagnosed rhabdomyosarcoma, melanosarcoma/-blastoma, spindle cell or nevoid carcinoma, and one associated with neuroblastoma. Absolute risk for NCM as well as oncogenic associations increases with LCMN size and the numbers of disseminated nevi in a linear, rather than a dichotomous, fashion.

For those patients opting for surgical intervention, the treatment should attempt to reduce the risk of developing cutaneous melanoma, while simultaneously optimizing esthetic and functional outcomes. Dr. Marghoob discussed work in preparation for publication in which three-quarters of respondents preferred their surgical scar over their original nevus because the scar was felt to be more socially acceptable, but urged the audience to also assist the other quarter of their patients who regretted surgery by associating psychological accompaniment with the management plan.

*Alon Scope* (Sheba) focused on the use of non-invasive, in vivo imaging techniques in the evaluation of pigmented skin lesions for the early detection of melanoma. Dermoscopic structures that can be observed within CMN include milia-like cysts, terminal hair, perifollicular pigmentary changes, globules, and network-like areas. Reflectance confocal microscopy (RCM) allows the examination of skin lesions at a cellular-level resolution. With dermoscopy and RCM, effective imaging depth is limited to the papillary and upper reticular dermis, and thus, these methods are recommended for the evaluation and monitoring of small to medium CMN that are relatively flat and superficial. In larger CMN, particularly ones that are elevated, thick or nodular, dermoscopic and RCM evaluations are less likely to be informative. Nonetheless, these techniques allow the dermatologist to undertake a kind of gross pathology at the bedside and avert unnecessary surgical interventions for many cases.

One precondition for a proper assessment of GCMN-associated melanoma risk and characteristics is to compare with the full range of melanomas from a similar age group. *Sven Krenzel* (Lübeck) summarized current knowledge about childhood cutaneous melanoma (ChM). The incidence of ChM is 3 per million per year for children under the age of 14 and 2 per 100 000 per year for adolescents between 15 and 19 years of age (SEER database). For comparison, adults in northern latitudes have incidences of 12–15 per 100 000 per year. Clinically, ChM – unlike the prevailing adult superficial spreading type – often present as nodular, pedunculated, or amelanotic lesions, sometimes simulating pyogenic granuloma. Diagnostic uncertainty is worsened by the fact that the histological demarcation from Spitz nevi is notoriously tricky. Lymph node metastasis is more

frequent in children and may occur in cases of atypical, but often benign pediatric melanocytic tumors. Regarding overall survival, children with melanoma starting before puberty generally have a better prognosis than older children. Only 20% of ChM develop in contiguity to a congenital nevus, and only 3% are intralesional to a GCMN. Melanoma in GCMN tends to arise from deeper tissue layers and often presents with a dedifferentiated, small-cell type histomorphology ('melanoblastoma'). Dr. Krengel presented preliminary results from a systematic literature review indicating that *fatal* melanomas in GCMN predominantly arise in early infancy (median, 2 years) and mostly affect children with multiple disseminated nevi.

Proliferative nodules in GCMN are rapidly growing masses that clinically and histopathologically simulate melanoma. *Jürgen Bauer* (Tübingen) reviewed the patterns of chromosomal aberrations occurring in proliferative nodules associated with melanocytic lesions. As demonstrable by comparative genomic hybridization arrays using DNA from paraffin-embedded tissue (a technical advantage over karyotyping of biopsies), proliferative nodules mostly show only numerical aberrations in atypical cellular foci. Melanoma, on the other hand, exhibits complex profiles with both numerical and structural abnormalities. In comparison, Spitz nevi display typical numerical aberrations only in particular chromosomes. The combination of histopathologic and cytogenetic criteria represents a highly specific means to distinguish proliferative nodules in GCMN from nevus-associated melanoma.

*Alain Taieb* (Bordeaux) presented his perspective on future therapeutic modalities for the treatment of GCMN and NCM. Spontaneous disappearance of pigment cells is observable in certain cases of melanocytic nevi, melanoma, and vitiligo. The study of these phenomena may, therefore, enable the development of non-surgical approaches to treating pigmented proliferations. Recent evidence suggests that a specific autoimmune/inflammatory response is triggered in vitiligo by CD8+ T-cell responses to certain tyrosinase variants. These variants, much like the haptening of tyrosinase effected by the depigmenting agent monobenzene, enhance immune surveillance, in contrast to melanoma-associated variants. This presentation stimulated speculation about the role of excess nevomelanocytes in the hair cycle, as follicles can be crowded, the cycle accelerated and the terminal hair in CMN of any size, coarser and darker. Discussion then turned to the chemotherapeutic use of RAS, RAF, or mTOR inhibitors in the treatment of NCM.

## Neurocutaneous melanocytosis

Neurocutaneous melanocytosis is a rare neurocutaneous syndrome defined by the presence of three or more CMN in conjunction with pigmented deposits in the

central nervous system (CNS), either meningeal melanocytosis or CNS melanoma. *Yasmin Khakoo* (New York) gave us an advance look at her group's study of central nervous system abnormalities in children with NCM. In a retrospective review of NCM referrals to the pediatric neurology service at the Memorial Sloan Kettering Cancer Center between 2003 and 2010, fourteen patients with NCM were identified, of whom eight are still alive. Diffuse leptomeningeal deposits or confirmed meningeal melanoma were associated with most of the deceased cases. While more than a third of the living patients remained asymptomatic at last evaluation, the mean age of presentation of neurological symptoms, such as epilepsy and hydrocephalus, was before 2 years of age. Other observations in these NCM patients include a Dandy Walker malformation, a benign spindle-cell tumor, dorsal arachnoid cysts (three patients who have been asymptomatic and stable over time, but are under 3 years old), and three patients with profound developmental delay. NCM can be associated with hamartomous-like disruption of the underlying neuronal architecture.

*Marcos Tatagiba* (Tübingen), in his presentation of neurosurgical approaches to melanocytic neoplasms of the central nervous system, highlighted difficulties in determining the malignant potential of any given melanocytic tumor of the leptomeninges of the brain or the spine. The neutral denomination 'meningeal melanocytoma' reflects the spectrum of these tumors of intermediate to low malignant potential, somewhere between melanoma and nevus; transformation from a named melanocytoma to a malignant CNS melanoma has been described. Spontaneous, circumscribed tumors most frequently occur in the posterior fossa, Meckel's cave, and the thoracic spinal cord, where normal extracutaneous melanocytes congregate and are usually identifiable by magnetic resonance imaging because of their melanin content. Neurological deficits are mainly caused by compression of neural structures. Whenever possible, complete tumor resection should be performed; a video of one such intervention was projected. Post-surgical radiation therapy is strongly recommended based on a retrospective review of all published cases.

## Surgical options for GCMN treatment

Newly developed surgical techniques used for large skin defects after severe burn wounds, as well as reconstructive procedures after burns, can partially also be applied to children with giant congenital nevi. *Clemens Schiestl* and *Thomas Biedermann* (Zürich) in their joint talk, presented recent developments from their multidisciplinary team in skin tissue engineering. The application of a sophisticated two-layered autologous skin substitute to children with burn wounds is at an advanced stage of clinical testing. It presents the advantages of a non-cross-linked collagen hydrogel dermal equivalent,



which is rapidly revascularized, and growth in a custom silicon transplant chamber to obtain particularly large surfaces. With the help of illustrative cases, advantages and limitations of this method for the treatment of children with GCMN were presented.

On a case-by-case basis, complete excision of a GCMN may be impossible. *Rainer Rompel* (Kassel) presented his experience with hundreds of patients for whom dermabrasion and/or curettage were safe and effective means to reduce the nevomelanocytic load of the epidermis and upper dermis, to improve surveillance. Because of optimal wound healing and incomplete maturation of the skin structure at this age, the procedures are best performed from the 6th week of life and completed, if iterative, in the first year. An experienced interdisciplinary team of dermatological surgeons, pediatricians, and anesthesiologists is crucial for the success of this method. The ablative Erbium YAG laser can be a therapeutic alternative for difficult locations such as eyelids, ears, and the genital area. Recurrent pigmentation after dermabrasion is often observed, especially in smaller or facial nevi, and in older patients, but is preferable to the potential hypertrophic scarring that can accompany deeper ablations. Dermabrasion may be combined with full-thickness excisional strategies. Some discussion was held about a compensatory effect dermabrasion that might induce in remaining nevus cells; however, among the handful of reports of melanoma arising in hundreds of dermabraded GCMN, they were found between two and twenty years following intervention.

*Helmut Breuning* (Tübingen) presented results from 60 children with GCMN treated by early serial excisions and natural enforced skin expansion. A high-tension technique ('power stretching') with intracutaneous double butterfly sutures, after extensive loosening of the adjacent nevus-free skin, was developed to close long wounds. This surgical procedure takes advantage of the small absolute size and the high skin elasticity of the first year of life. For a total of 204 excisions (mean, 3.5 per child), a good esthetic and functional outcome was achieved in most of the cases by this sutural reinforcement.

In his keynote lecture, *Bruce Bauer* (Chicago, USA,) demonstrated his results with the use of more than 2300 tissue expanders in over 1000 surgeries in over 400 patients affected with large and giant CMN, with a follow-up as long as 30 years. This vast experience has led to clear regional considerations in the choice of expander size, flap design, and sequence of procedures. Expanded transposition and rotation flaps are preferable over advancement flaps for many reconstructions. Weekly expansion over 11–12 weeks is typical. Using an internal remote port allows outpatient filling of the expander(s) in most of the cases, and a case was made for parental education and involvement in this procedure. Tissue expansion is the 'workhorse' treatment

modality for scalp and forehead nevi and for GCMN of the trunk. Nevi that cross multiple facial units may require combination with full-thickness skin grafts or serial expansions. Expansion of the extremities is limited by the geometry and the difficulty of moving flaps in an axial direction. In GCMN of the upper extremity, large expanded flaps from abdomen/flank/back can provide optimal esthetic and functional treatment. Free tissue transfer and expanded pedicle flaps offer unconventional but effective means of dealing with GCMN of the lower extremity. Regulatory restrictions on the availability of certain preferred expanders across continents were lamented during the discussion, and osmotic expanders not recommended until speed of filling can be better regulated.

Better clinical indicators and diagnostic markers in the future will enable more doctors and their patients to be comfortable with the proactive choice of no further surgical intervention when the decision is based on risk of transformation. However, interventions may still play an important role in the psychological growth of affected children. For this reason, an interdisciplinary surgical plan should be broached in the first months of life, taking into account all established therapeutical methods.

### **Patient and family initiatives in medical research and psychosocial management**

In her keynote address about the psychosocial situation of children with GCMN and their families, *Ornella Masnari* (Zürich) presented preliminary results from the 'Stigmatization in children and adolescents with facial burns or birthmarks' project (<http://bit.ly/Stigma-study>). Data were obtained from a cohort of 91 children between 9 months and 16 years with facial burns, port-wine stains, hemangiomas, or GCMN through standardized interviews with 31 affected children and adolescents over the age of seven and from 83 parental reports, using standardized questionnaires. A large majority of the interviewed children had received expressions of pity, been stared at or drawn unwanted attention, and more than one-quarter reported outright hostile behavior from other children. Parental descriptions of stigmatizing experiences encountered by their children underestimated numbers of occurrences, but significant associations were found in both child and parent groups between social rejection and increasing age or size of the facial lesion, and not with gender. Of children who did not report feeling stigmatized, these were better adjusted than the norm for age-matched children without facial marks, while fully half of the stigmatized children demonstrated behavioral problems. Both physicians and patient representatives confirmed these findings after the presentation. They discussed how much to adjust the child physically, as opposed to adjusting the psychological support provided to parents and indirectly or directly to the children or to adjusting negative attitudes in society at large with media

campaigns. In particular, there is currently little follow-up from parents to whom psychological counseling is recommended. Perceived control over a birthmark may be less than over a scar because of a medical intervention, a hypothesis concordant with earlier studies. General consensus was that much work remains to do in this area.

*Mark Beckwith* (Bartlesville) briefly recapitulated the history of Nevus Outreach, Inc., of which he is executive director, and introduced the other patient association attendees present. Nevus Outreach was founded in 1997 by three families affected by GCMN. Over time, it has become arguably the largest and the most active patient association in the world. Because of the federative actions undertaken by Nevus Outreach, more than 60 people with a GCMN themselves or with an affected family member attended this conference from 11 different countries and as many currently constituted advocacy groups (some countries with more than one, some with none).

The study of rare diseases requires the collaboration of physicians, scientists, and patients. Disease-specific registries are an important means to better study and understand these conditions. Pinch hitting, Dr. Marghoob summarized past cohort studies and GCMN registry data published in the literature. The progress in GCMN research that has already been made by the

evaluation of existing registries and the constraints imposed by the lack of statistical power are strong arguments for the unification of the currently existing databases into a collaborative and prospective international GCMN registry.

During the final recapitulation, the patient associations put forth two initiatives: the first, committing to support and participate in the above-mentioned GCMN/NCM registry and a second, agreeing on an Internet-based, multilingual and globally accessible GCMN/NCM patient information clearinghouse. This platform will serve both as a portal to the registry and provide links to each of the worldwide patient associations, serving researchers, physicians, and patients alike; more information will be made available on the progress of this undertaking on <http://www.nevus.org>. Translations will be initially provided by volunteer scientists and doctors in these languages: English, German, French, Spanish, Portuguese, Italian, and Dutch. A working group was constituted to standardize the data categories and resource links to be included in the new registry, with the goal of inaugurating it by the next Expert Meeting, projected to take place in 2013. A first brainstorming session will take place on the sidelines of the International Pigment Cell Conference in Bordeaux, France, on September 24, 2011.